

Arteriovenous Loop Grafts for Free Tissue Transfer in Complex Lower Limb Defects

WAEEL M. AYAD, M.D.; ABDELNASER H. MOHAMMED, M.D.; HANY M. ISMAIL, M.D.; MOHAMED OSAMA OUF and AMR M. ELBATAWY, M.Sc., M.R.C.S.

The Department of Plastic and Burn Surgery, Faculty of Medicine, Al-Azhar University

ABSTRACT

Background: Arteriovenous (AV) loop grafts are a type of vascular conduit that can be used to support free tissue transfer. Wounds of various etiologies may require free tissue transfer, and the AV loop graft is a useful adjunct when adjacent blood supply is inadequate.

Aim: The goal of the present article is to report on a clinical series of complex microvascular reconstructions of the extremities using one- or two stage vascular loops as recipients, and to discuss possible indications and contraindications.

Patients and Methods: Between January 2013 and December 2015, 20 Latissimus Dorsi (LD) muscle flaps were used for lower limb reconstruction preceded by arteriovenous loop as a recipient vessel 2 to 13 days before the operation. The patient group meeting the inclusion criteria of the study comprised two females and 18 males ranging from 10 to 45 years of age. AV loop lengths, total operating times, times from skin incision to initiation of microsurgery, and complications of the procedure were analyzed.

Results: Twenty microsurgical free tissue transfers were performed in 20 patients. Two flaps (10%) were revised for venous thrombosis and salvaged. Partial necrosis of the distal part of three flaps (15%) observed and managed conservatively. No donor site morbidity, All flaps were survived.

Conclusions: In complex injuries, the arteriovenous loop is a safe and reliable adjunctive for free flap transfer. Delaying flap transfer may be reasonable in some circumstances.

Key Words: AV loop graft – Lower limb – Defects.

INTRODUCTION

Complex wounds, such as those encountered in patients with diabetes, trauma, or radiation injury, may be difficult to heal. When primary closure of a large soft tissue defect is impossible and healing by secondary intention fails, coverage with free tissue transfers should be considered [1].

Success of free tissue transfer depends to a large extent on the microvascular anastomosis, the quality of the recipient vessels, and the size and-

caliber match between the recipient and flap vessels. Following high energy trauma, radiation or chronic inflammation, severe injury to the intima of vessels in proximity to the defect preclude their use as recipient vessels for free tissue transfer. In such cases, the use of the arteriovenous (AV) loop graft technique can be employed [2].

Classically, this has been accomplished using vein grafts, with a reported increase in complication rates up to four fold (with a higher rate of vascular thrombosis). Vein grafts significantly prolong ischemia time of the flap, and adjusting length is not straight forward. In an attempt to overcome the drawbacks of vein grafting and to use them in a more rational way, the concept of the temporary arteriovenous fistula or vascular loop was developed [3].

PATIENTS AND METHODS

In this study, we present our experience in using the AV loop in major catastrophic lower limb wounds as a pertinent solution to overcome the unfavorable condition of the recipient vessels.

Between January 2013 and December 2015, 20 LD muscle flaps were used for post-traumatic lower limb reconstruction in Al-Azhar University Hospitals. The study included 18 males and two female patients with a mean age of 27.5 years (range: 10 to 45 years). The defects were located in the upper two thirds of the leg in 12 cases and the lower third of leg and ankle region in 8 cases. All defects were reconstructed 2-3 weeks after trauma. The AV loop was constructed seven days before flap transfer, using the contralateral great saphenous vein in 18 cases and the cephalic vein in two cases. The LD was transferred as a musculocutaneous flap in 15 cases and as a chimeric flap with slips from serratus Anterior (SA) muscle in

5 cases. Clinical evaluation of the patients for proper assessment of the site and size of the defect and underlying exposed critical structures. Plain X-ray, Doppler examination, and C.T. angiography were done preoperatively in all cases.

Technique:

Two teams were operating simultaneously. One team for harvesting the great saphenous (16 cases) (Fig. 1) or cephalic veins (4 cases) and the other team for exploration and controlling of femoral artery and its venae comitantes (16 cases) or great saphenous vein above the knee joint (4 cases). Spinal epidural anesthesia was employed in 16 patients and general anesthesia in 4 patients. Lazy S incision at the lower two thirds of the medial aspects of the thigh (Fig. 4) and the femoral vessels and great saphenous vein were dissected and controlled while the contralateral great saphenous veins or cephalic veins were harvested simultaneously.

Great saphenous vein or cephalic vein were flushed from their distal ends with a heparin solution (5000 units/500mL saline, using 22-gauge cannula) (as in Fig. (2)] after clamping their proximal ends with a vascular clamp. During flushing, the veins were checked for any leakage which were hemoclipped. Capacious tunnel at the medial aspect of the lower thigh and knee was created to accommodate the A-V loop. The arterial anastomosis (end to side) with the femoral artery and venous anastomoses (end to end) with the great saphenous vein or femoral venae comitantes were achieved using 9/0 polypropylene. At the time of anastomosis, the anesthesiologist was asked to maintain adequate blood pressure and giving a single dose of intravenous heparin (100 IU/kg). The constructed A-V loop (Fig. 3) were retrieved through the tunnel to be within 3 cm of the proximal edge of the defect. Two loose sutures (9/0 polypropylene) between the adventitia of the loop and bed of the tunnel to avoid its kinking. Then adequate hemostasis and wound closure in layers were done as in Fig. (4).

Clinical and Doppler Monitoring of the A-V loop at skin mark over the site of anastomosis. After 7 days, the second stage was done. A latissimus dorsi myocutaneous free flaps or latissimus-dorsi myocutaneous flap with serratus anterior were harvested. Then the A-V loops were re-explored and divided near the defect. Vascular anastomoses and flap inseting were done. STSG were harvested for coverage of the muscle as in the demonstrated cases (1,2) and in Figs. (5-7) respectively.

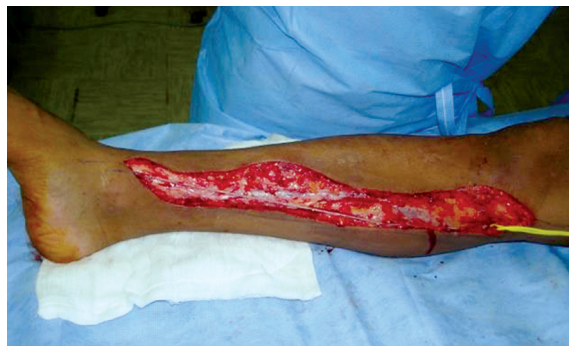

Fig. (1): Incision for harvesting the great saphenous vein.

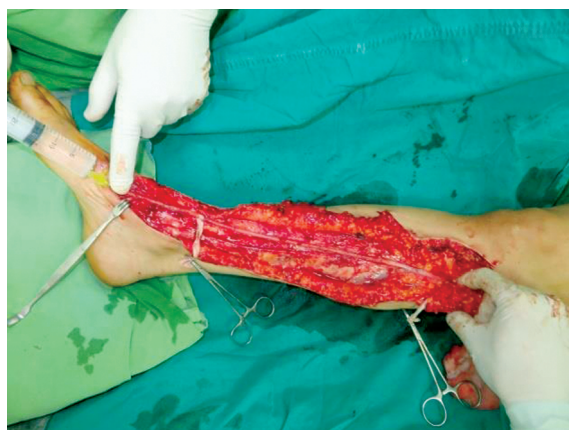

Fig. (2): Flushing the vein with heparin for thrombolysis and detection of any leak.

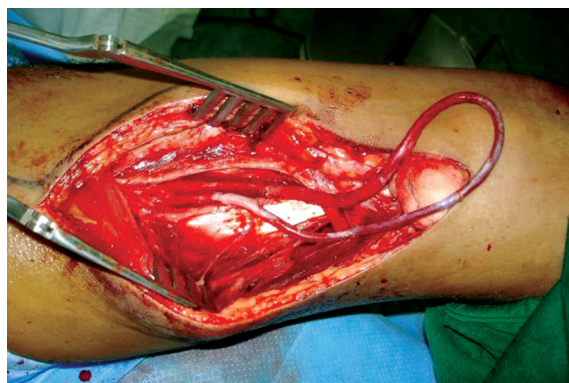

Fig. (3): The constructed loop after anastomosis to the femoral vessels (artery and vein).

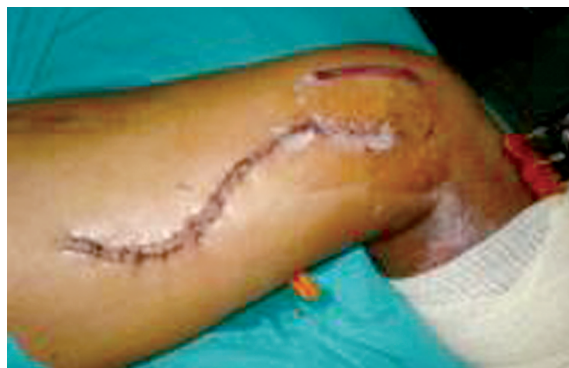

Fig. (4): Show the closed lazy S incision along the medial aspect of the leg.

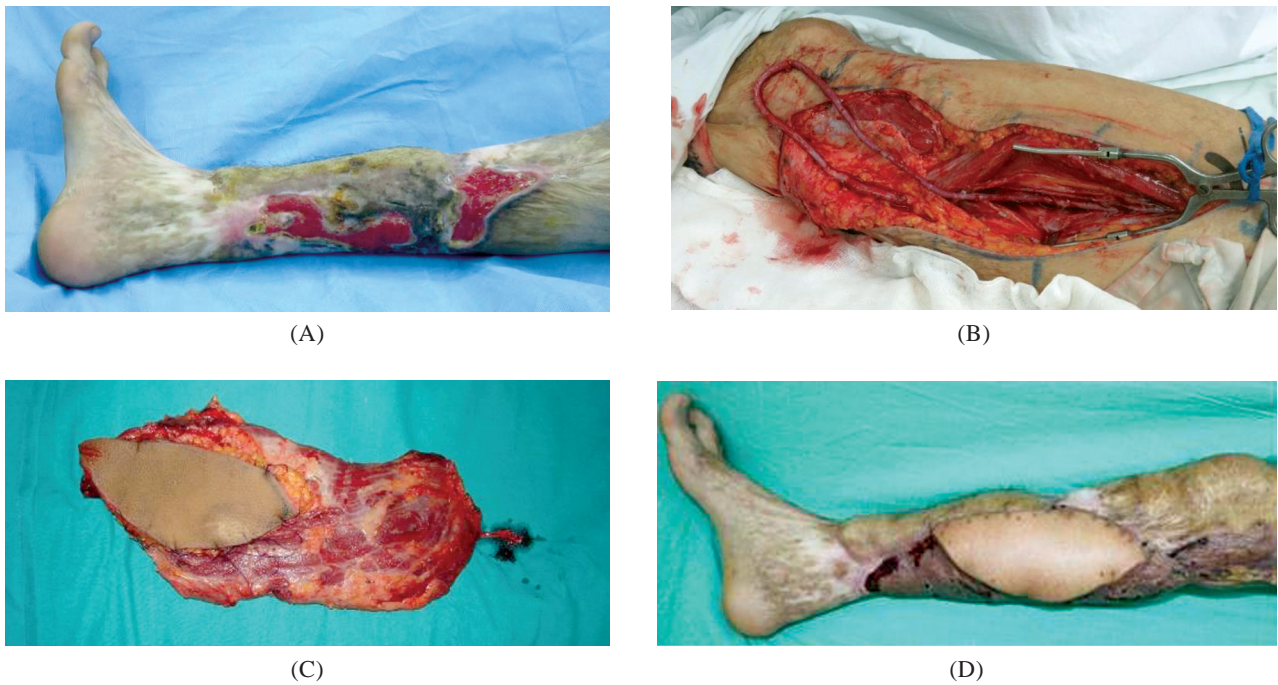


Fig. (5): Case (1): (A) Male patient 54 years old with a longstanding trauma to the right leg with recurrent ulcerations in the scar (B) After anastomosis of the vein to femoral artery (end to side) and saphenous vein in the affected leg, (C) The harvested contralateral Latissimus Dorsi myocutaneous flap (D) Long term follow-up following reconstruction by LD flap in a second stage.

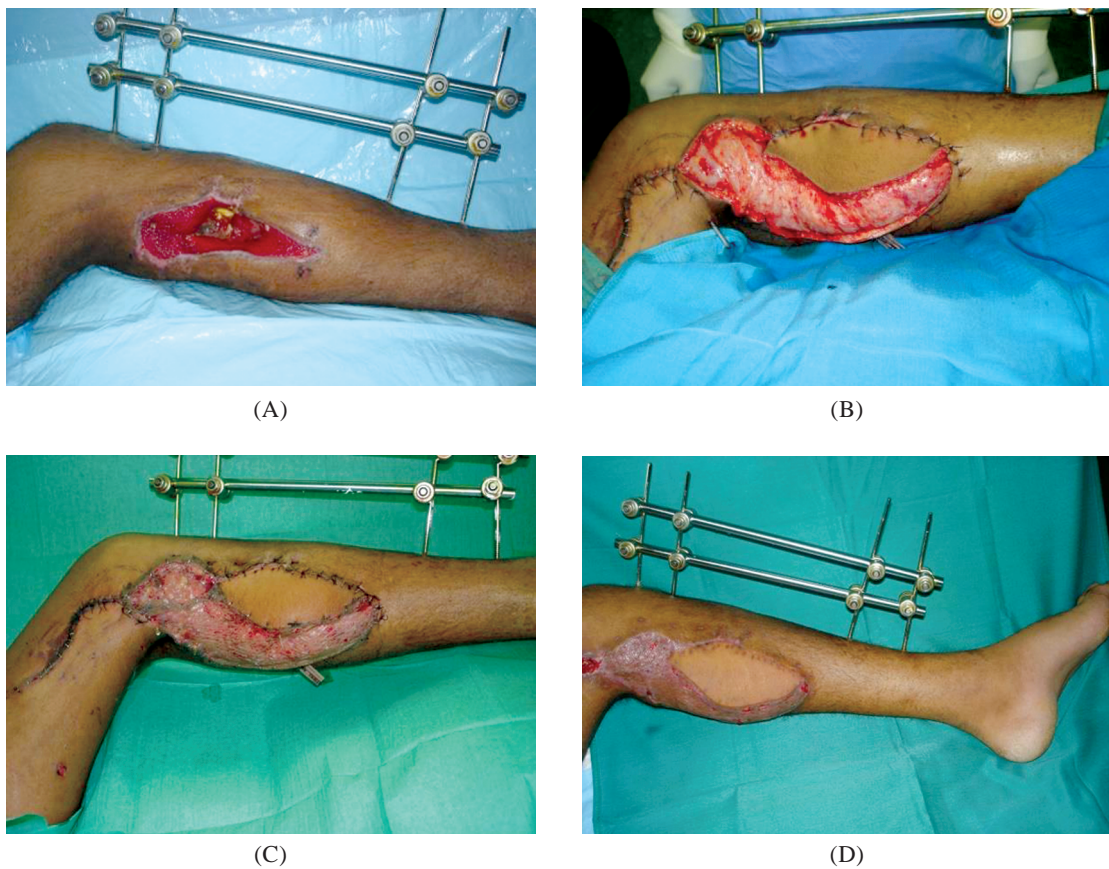

Fig. (6): Case (2): (A) Male patient 30 years old with a post traumatic fracture of right upper two thirds of the tibia with exposed plate, (B),(C) Immediately after the second stage of complete coverage with LD myocutaneous flap and STS graft (D) One month later. Following reconstruction by LD flap in a second stage.

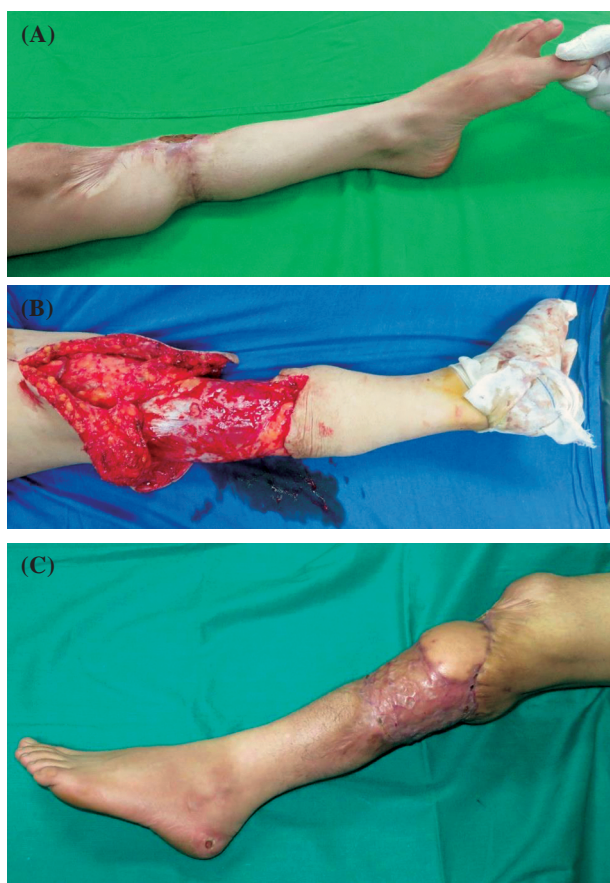

Fig. (7): Case 3: (A) Female patient 40 years old with a long standing trauma to the left leg with recurrent ulceration in the scar and atrophy in the leg, (B) After complete release of the scar and excision of the ulcer, (C) After reconstruction by LD flap in a second stage after AV loop, note replacement of all unstable scars with the muscle tissue.

RESULTS

Twenty free microsurgical free tissue transfer were performed in twenty patients. The mean age of the patients 27.5 (Table 1). The results are summarized in Table (1). The total operation time (8-11 hours) with a mean 9.5. There was no occlusion of vascular loops before the second stage for lower limb reconstruction. Venous thrombosis occurred in 2 free flaps (case no. 4,12) on postoperative day 2. Re-exploration rate was 10%. The patients returned to the operative room and exploration revealed venous thrombosis within the pedicle not related to the loop. The venous anastomosis was revised and the flaps survived. Three free flaps (15%) (cases no. 8,15,19) developed distal partial necrosis that managed conservatively. No occlusion of the A-V loops and all flaps survived (100%) and limb salvage was achieved in 100% of patients. There was no complications related to the Steal Phenomenon. Regardless healing by hypertrophic scar that respond to local wound care in six cases, no donor site morbidity was observed.

Table (1): Characters and complications of the studied cases.

Case	Age (yr)	Sex	Defect	A-V loop length	Complications
1	22	Female	Upper 2/3 of the leg	23cm	–
2	32	Male	Lower 1/3 of leg	28cm	–
3	26	Female	Upper 2/3 of the leg	22cm	–
4	45	Male	Upper 2/3 of the leg	23cm	Venous thrombosis
5	33	Male	Upper 2/3 of the leg	23cm	–
6	25	Male	Lower 1/3 of leg	26cm	–
7	25	Male	Upper 2/3 of the leg	21cm	–
8	30	Male	Upper 2/3 of the leg	22cm	Partial distal necrosis
9	40	Male	Upper 2/3 of the leg	23cm	–
10	31	Male	Upper 2/3 of the leg	22cm	–
11	22	Male	Upper 2/3 of the leg	23cm	–
12	30	Male	Lower third of leg	25cm	–
13	10	Male	Lower 1/3 leg	25cm	–
14	31	Male	Lower 1/3 of leg	26cm	Venous thrombosis
15	41	Male	Lower 1/3 of leg	25cm	Partial distal necrosis
16	17	Male	Upper 2/3 of leg	21cm	–
17	23	Male	Lower 1/3 of leg	25cm	–
18	18	Male	Upper 2/3 of leg	23cm	–
19	23	Male	Upper 2/3 of leg	23cm	Partial distal necrosis
20	22	Male	Lower 1/3 of leg	26cm	–

DISCUSSION

Large complex defects of the lower limbs present a challenging problem in reconstruction. These large defects caused by an extensive trauma and usually associated with lack of the nearby vessels available for free tissue transfer. In such cases the use of vein graft or arteriovenous loop is essential to extend vascular supply to defects requiring reconstruction.

Benjamin et al., [1] reported that the interpositional vein grafts are often used to bridge a gap between free flap vessels and healthy recipient vessels. The use of vein grafts, although necessary and useful at times, has been associated with a higher rate of vascular thrombosis.

In 1987, Genga et al., used a temporary arteriovenous loop prior to free myoosseous flap transfer, in an attempt to overcome the drawbacks of vein grafting and to use them in a more rational way [4]. They used it to solve the diabetic wounds problems. Atiyeh et al., reported successful limb salvage in diabetics with non-healing foot wounds. Of the 7 patients with diabetic foot ulcers 6 were successfully treated with free tissue transfer supported by AV loop graft [5,6] and Sunar et al.,

reported limb salvage in 11 of 13 treated diabetic ischemic extremities [7]. In our study all wounds were posttraumatic. Lin et al., described a large series of AV loop grafts used in traumapatients and achieved a 91% limb salvage rate [8].

In our series of a twenty patients we used arteriovenous loops in a 2-stages procedure. The arteriovenous loops can be done as one or two stages procedures. Oswald et al. [9] performed a series of one stage procedure with success, and after reviewing both procedures, advocated this approach, based on a literature review that showed equal complication rates. A one-stage procedure has logistic and economic advantages over a two-stage free flap. Cavadas performed large series with 56 loops in 55 patients. The results were less pessimistic, with a 100 percent flap success rate, although 16 percent and 3 percent of the delayed and acute arteriovenous loops, respectively, occluded. In our series of twenty patients with twenty loops, the results were comparable to that reported by Cavadas [3], Sunar et al. [7] and Lin et al. [8] in their 2-staged procedure, where we had 100% flap survival rate, and no occlusion of AV loops (0%) but only limited flap necrosis in two cases (10%) that were managed conservatively.

A mean of six days was required as a maturation period for arteriovenous loops as mentioned by Cavadas [3] while Benjamin et al. [1] reported four days. In our series the second stage performed after 7 days of loop construction despite of that there is no experimental or clinical evidence of an optimal maturation period.

The latissimus dorsi myocutaneous flaps were used in our study, 15 cases as a musculocutaneous flap and five cases as a chimeric flap with three slips of serratus anterior muscle for coverage of post-traumatic leg defects with complete flap survival in 18 patients (18 cases) and partial flap necrosis in two cases). Cavadas reported the use of variety of free flaps including muscular, bone, osteocutaneous, and omental flaps for reconstruction of diabetic foot wounds and after trauma. All flaps performed were survived.

There are many advantage of delaying the flap transfer to the loop including short operative time, better maturation of the loop, and decrease the incidence of flap loss if done in one stage. The fact that arteriovenous loops are low-resistance, high-velocity circuits make thrombosis theoretically unlikely. Besides, endothelialization of the anastomotic lines will have taken place before actual flap transfer, making thrombosis unlikely at the proxi-

mal suture lines [10,11]. A two-stage procedure also permits turning a lengthy one-stage flap transfer (directly to the arteriovenous loop) into two shorter and easier surgical procedures (arteriovenous loop construction, and a straight forward flap transfer to optimal recipient vessels), which could be advantageous in patients with multiple comorbidities.

Assuming an appropriate size match, it is preferable to use a graft with a large diameter, such as the great saphenous vein, as the flow is directly proportional to the 4th power of the radius of the conduit. This provides higher flow rates for both the arterial and venous grafts. By doing so, however, consideration should be given to select a free flap with large caliber vessels to match that of the large vein graft [2], therefore, we used the LD in our series to get benefit from its large diameter vessels.

Delayed, two-stage arteriovenous loops have significant potential complications. The hemodynamic effects of arteriovenous shunting are well-described and are dependent basically on the amount of flow through the shunt [12]. Arteriovenous fistulas tend to decrease arterial pressure, increase peripheral and central venous pressure, and increase the ventricular preload. In a healthy patient with a low-flow fistula (such as the arteriovenous loops), the myocardial muscle increases the contractility and the stroke volume, and with a minor and transient increase in the heart rate, the hemodynamic disturbance of the fistula is corrected, while in patients with cardiac failure with low stroke volume, the added increase in preload cannot be compensated for and can precipitate a catastrophic heart failure or a myocardial infarction [13], as indeed occurred in one of the patients in the present series. Arteriovenous fistulas should be avoided in these patients, and two-stage loops should be formally contraindicated.

The other relevant side effect of delayed arteriovenous fistulas is the steal phenomenon [14]. If great resistance is present in the arterial tree downstream, the flow will preferentially run through the fistula, leading to the theoretical possibility of aggravating distal ischemia, mainly in diabetics. Although the possibility has been reflected in the literature, it has been reported very infrequently, and it did not occur in the series presented in this article [1].

It is our opinion, however, that a 2-stage approach divides the case into 2 more manageable procedures. Arteriovenous loop grafts can be con-

structed using methods similar to practicing vascular surgeons. They are a useful adjunct to extend the vascular supply to areas in need of free flap coverage but with inadequate adjacent arterial inflow or venous outflow.

Several studies have differed in their conclusions regarding the advantages and disadvantages of single versus two-stage AVF formation and its outcome on the success free tissue transfer (1,7–10). In this study, we examined the outcomes of free flaps requiring long vein grafts (20cm) for arterial defects, either with or without venous defects, for completion of the reconstructions. By comparing results achieved using different recipient vessels, complications associated with each, different staging protocols and different length vein grafts or arteriovenous fistulas, conclusions are made regarding the optimal method and the algorithm for usage of these grafts 2.

Conclusion:

Coverage of complex soft tissue wounds can be difficult and may require a multispecialty approach. Basic vascular surgical techniques can be employed to create vascular conduits for support of free flaps when no adjacent vessels are available. These techniques have been shown to have successful application in the coverage of wounds of various etiologies including trauma, radiation, diabetes, and malignancy.

REFERENCES

- 1- Benjamin Lind, Walter McCarthy, Gordon Derman and Chad Jacobs: Arteriovenous Loop Grafts for Free Tissue Transfer. *Vascular and Endovascular Surgery*, 46 (1): 30-33.
- 2- Chih-Hung Lin, M.D.; Samir Mardini, M.D.; Yu-Te Lin, M.D.; Jiun-Ting Yeh, M.D.; Fu-Chan Wei, M.D.; FACS and Hung-Chi Chen, M.D.: FACS2w Sixty-Five Clinical Cases of Free Tissue Transfer Using Long Arteriovenous Fistulas or Vein Grafts *The Journal of Trauma Injury, Infection, and Critical Care*, Volume 56 • Number 5, 1107-17.
- 3- Cavadas P.C.: Arteriovenous Vascular Loops in Free Flap Reconstruction of the Extremities *Plast. Reconstr. Surg.*, 121: 514, 2008.
- 4- Grenga T.E. and Yetman, R.J.: Temporary arteriovenous shunt prior to free myosseous flap transfer. *Microsurgery*, 8: 2, 1987.
- 5- Atiyeh B.S., Khalil I.M., Hussein M.K., AlAmm C.A. and Musharafieh R.S.: Temporary arteriovenous fistula and microsurgical free tissue transfer for reconstruction of complex defects. *Plast. Reconstr. Surg.*, 108 (2): 485-488, 2001.
- 6- Atiyeh B.S., Sfeir R.E., Hussein M.M. and Husami T.: Preliminary arteriovenous fistula for free-flap reconstruction in the diabetic foot. *Plast. Reconstr Surg.*, 95 (6): 1062-1066, 1995.
- 7- Sunar H., Aygit C.A., Afsar Y., Halici U. and Duran E.: Arterial and venous reconstruction for free tissue transfer in diabetic ischemic foot ulcers. *Eur. J. Vasc. Endovasc. Surg.*, 27 (2): 210-215, 2004.
- 8- Lin C.H., Mardini S., Lin Y.T., Yeh J.T., Wei F.C. and Chen H.C.: Sixty-five clinical cases of free tissue transfer using long arteriovenous fistulas or vein grafts. *J. Trauma*, 56 (5): 1107-1117, 2004.
- 9- Oswald T.M., Stover S.A., Gerzenstein J., et al.: Immediate and delayed use of arteriovenous fistulae in microsurgical flap procedures: A clinical series and review of published cases. *Ann. Plast. Surg.*, 58 (1): 61-63, 2007.
- 10- Baxter T.J., O'Brien B.M., Henderson P.N. and Bennett R.C.: The histopathology of small vessels following microvascular repair. *Br. J. Plast. Surg.*, 59: 617-622, 1972.
- 11- Servant J.M., Ikuta Y. and Harada Y.: A scanning electron microscope study of microvascular anastomoses. *Plast. Reconstr. Surg.*, 57: 329-334, 1976.
- 12- John A.B., Gabor K. and Gabor M.R.: *Flow-Dependent Regulation of Vascular Function*. New York: Oxford University Press, 178-203, 1995.
- 13- Dean W.R.: The stream-line motion of fluid in a curved pipe. *Philosophy Series*, 75: 673, 1928.
- 14- Sonntag B.V., Murphy Jr. R.X., Chernofsky M.A. and Chowdary R.P.: Microvascular steal phenomenon in lower extremity reconstruction. *Ann. Plast. Surg.*, 34: 336-339, 1995.